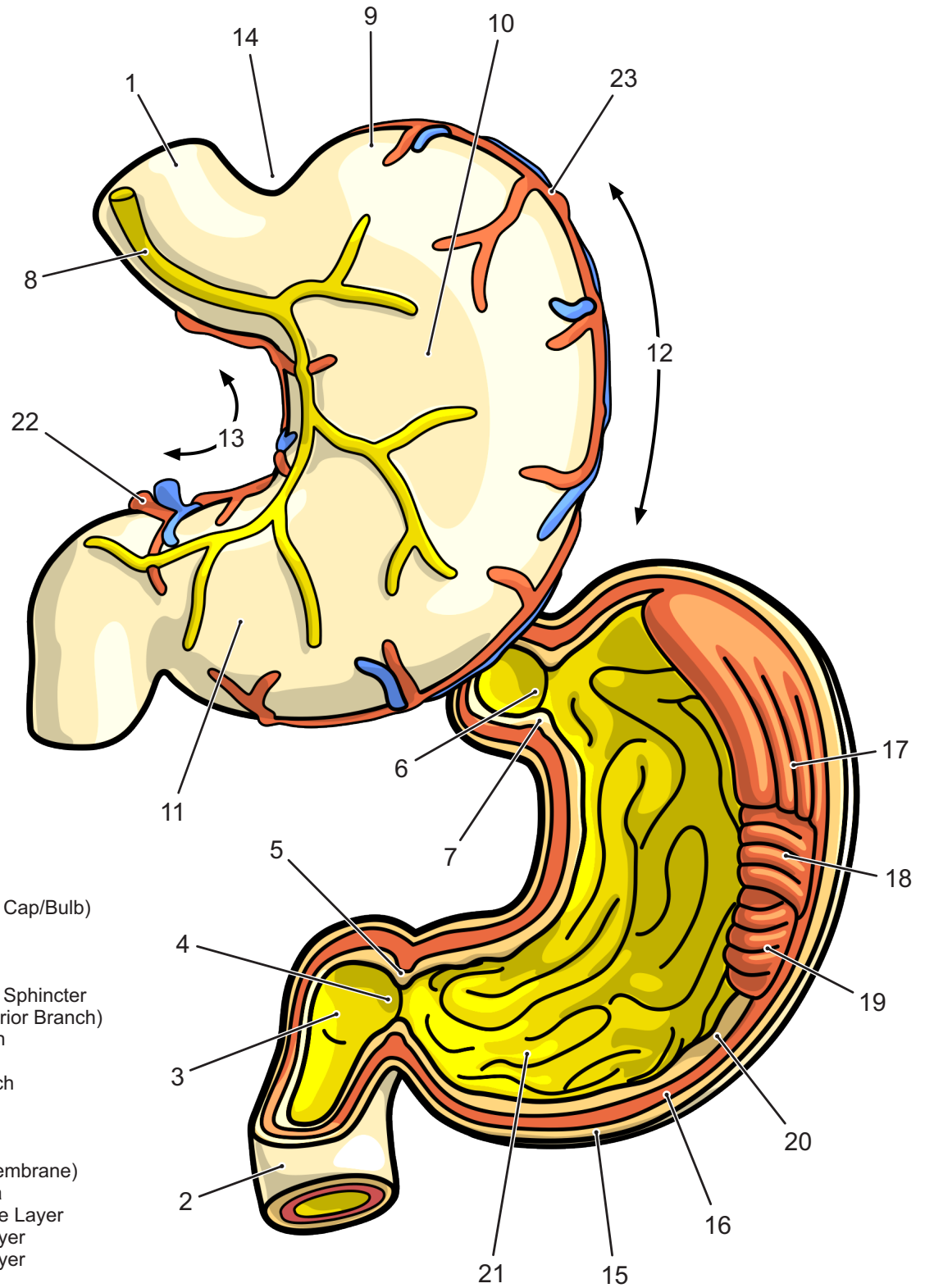


# Internal and External Structure of the Human Stomach



- 1·Esophagus
- 2·Duodenum
- 3·Ampulla (Duodenal Cap/Bulb)
- 4·Pylorus
- 5·Pyloric Sphincter
- 6·Cardiac Orifice
- 7·Lower Esophageal Sphincter
- 8·Vagus Nerve (Anterior Branch)
- 9·Fundus of Stomach
- 10·Body of Stomach
- 11·Antrum of Stomach
- 12·Greater Curvature
- 13·Lesser Curvature
- 14·Cardiac Notch
- 15·Serosa (Serous Membrane)
- 16·Muscularis Externa
- 17·Longitudinal Muscle Layer
- 18·Circular Muscle Layer
- 19·Oblique Muscle Layer
- 20·Mucosa
- 21·Ruggae of Mucosa
- 22·Gastric Artery
- 23·Gastropyloric Artery