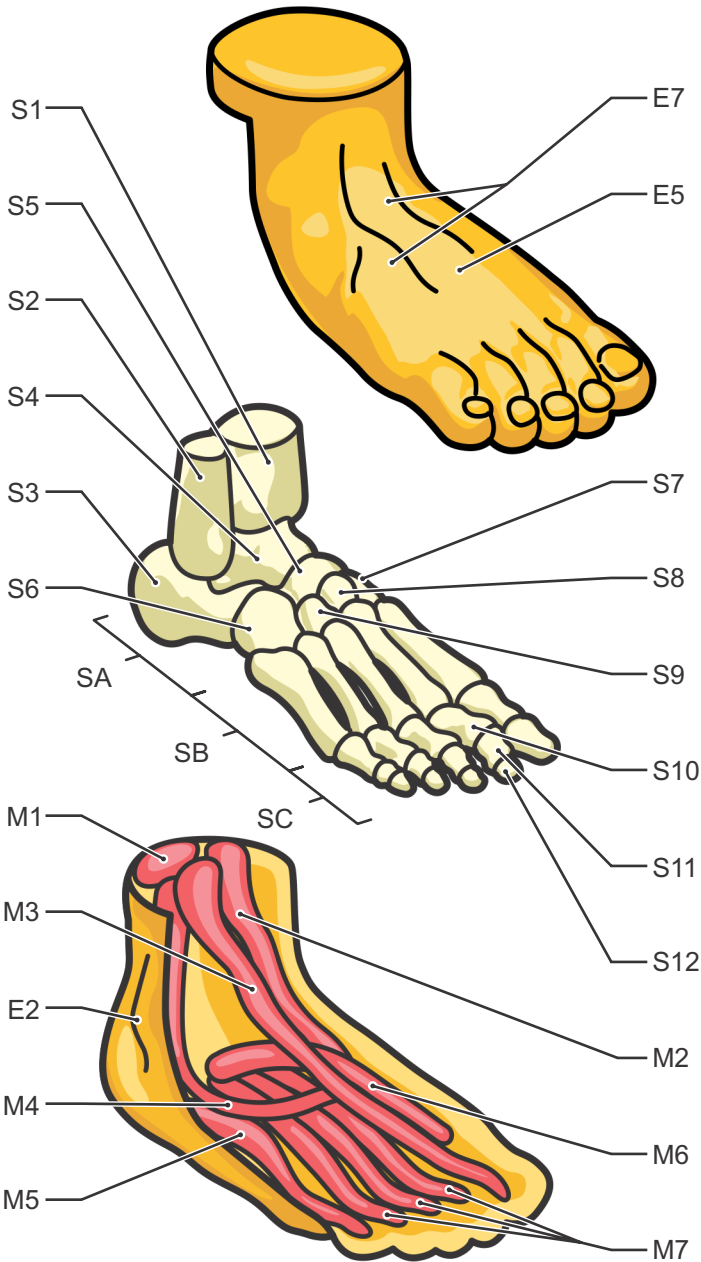
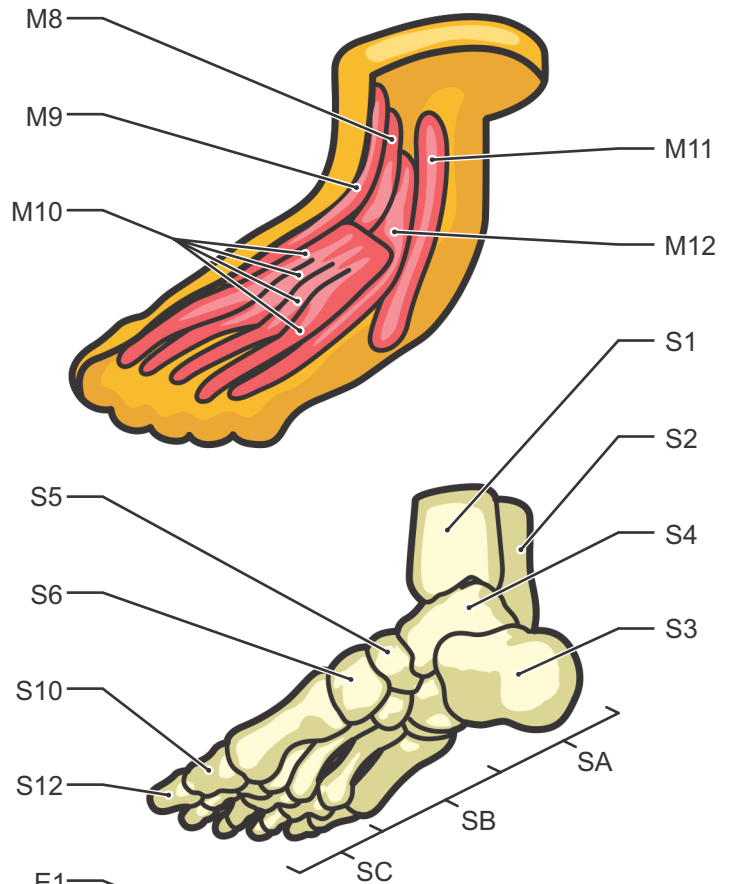


The Human Foot



- E1·Medial Malleolus
- E2·Lateral Malleolus
- E3·Medial Arch
- E4·Lateral Arch
- E5·Dorsal Surface
- E6·Plantar Surface
- E7·Superficial Dorsal Veins
- S1·Tibia
- S2·Fibula
- SA·Tarsals
- S3·Calcaneus

- S4·Talus
- S5·Navicular
- S6·Cuboid
- S7·Medial Cuneiform
- S8·Intermediate Cuneiform
- S9·Lateral Cuneiform
- SB·Metatarsals
- SC·Phalanges
- S10·Proximal Phalanges
- S11·Middle Phalanges
- S12·Distal Phalanges



- M1·Achilles Tendon
(attaches to Gastrocnemius and Soleus muscles)
- M2·Tibialis Posterior
- M3·Flexor Digitorum Longus
- M4·Peroneus Longus
- M5·Abductor digiti minimi
- M6·Abductor Hallucis
- M7·Flexor Digitorum Brevis
(on top of Flexor Hallucis Longus)
- M8·Extensor Hallucis Longus
- M9·Tibialis Anterior
- M10·Extensor Digitorum Brevis
- M11·fibularis Tertius
- M12·Extensor Digitorum Longus

