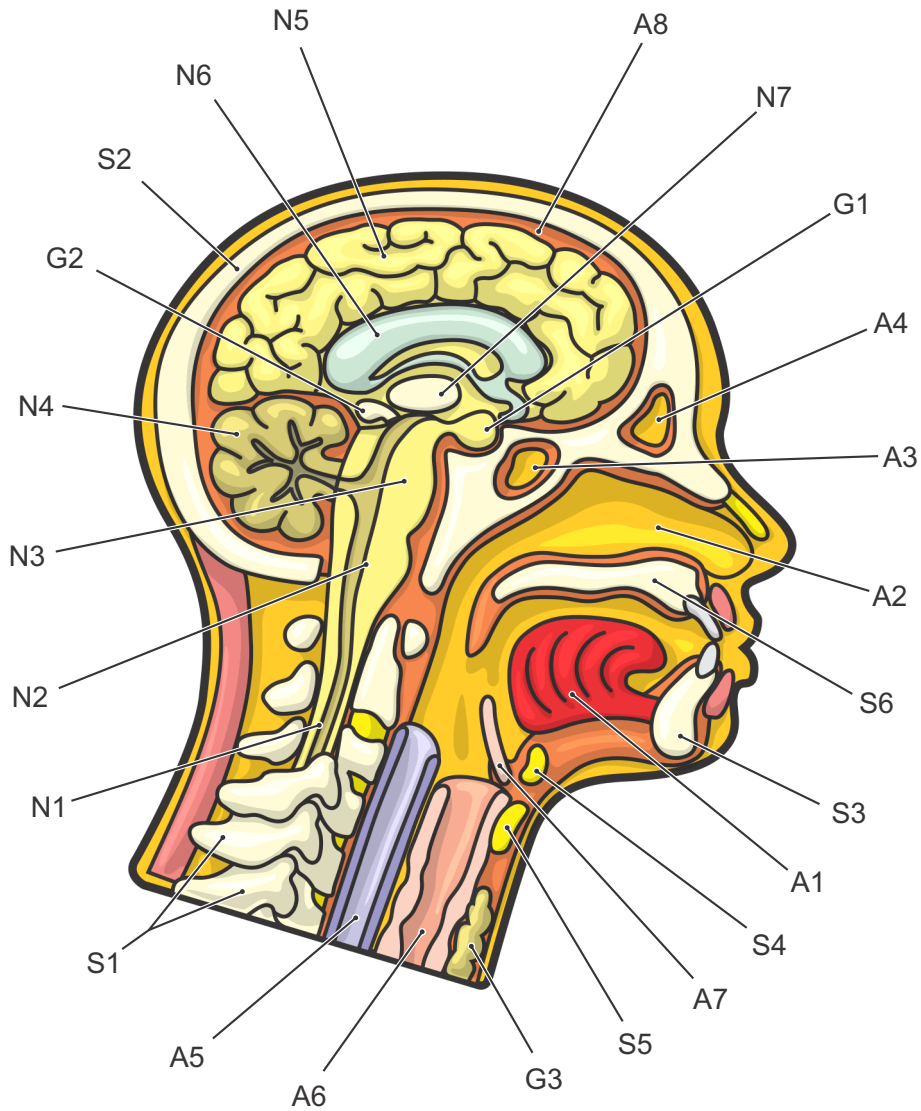


Sagittal Section of the Human Head

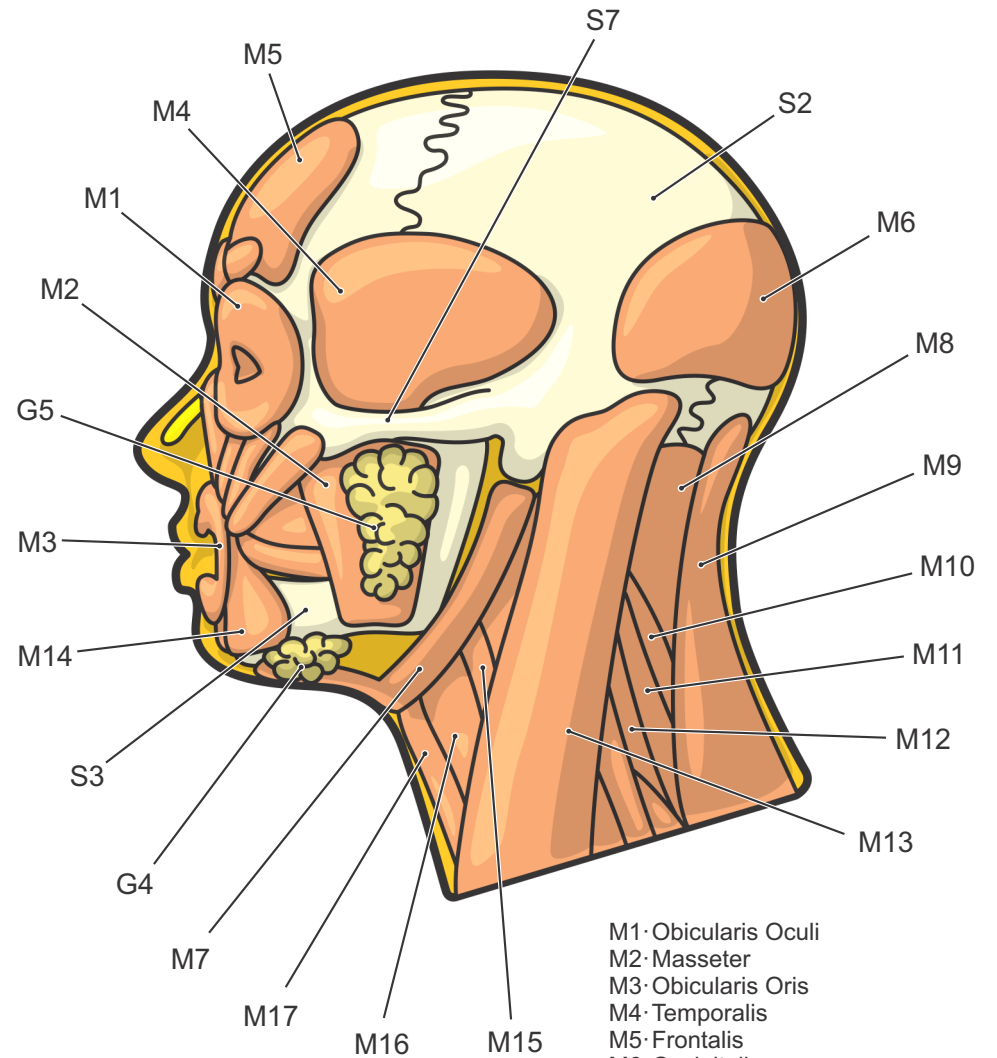


G1-Pituitary Gland
G2-Pineal Gland
G3-Thyroid Gland
G4-Submandibular Gland
G5-Parotid Gland

S1-Vertebrae
S2-Cranium
S3-Mandible
S4-Hyoid Bone
S5-Thyroid Cartilage
S6-Maxilla (hard palate)
S7-Zygomatic Arch

N1-Spinal Cord
N2-Medulla Oblongata
N3-Pons
N4-Cerebellum
N5-Cerebrum
N6-Corpus Callosum
N7-Thalamus

External Anatomy of the Human Head



M1-Obicularis Oculi
M2-Masseter
M3-Obicularis Oris
M4-Temporalis
M5-Frontalis
M6-Occipitalis
M7-Digastricus
M8-Levator Scapulae
M9-Trapezius
M10-Scalenus Posterior
M11-Scalenus Medius
M12-Scalenus Anterior
M13-Sternocleidomastoid
M14-Depressor Anguli Oris
M15-Thyrohyoid
M16-Omohyoid
M17-Sternohyoid

A1-Tongue
A2-Nasal Cavity
A3-Sphenoidal Sinus
A4-Frontal Sinus
A5-Esophagus
A6-Trachea
A7-Epiglottis
A8-Meninges