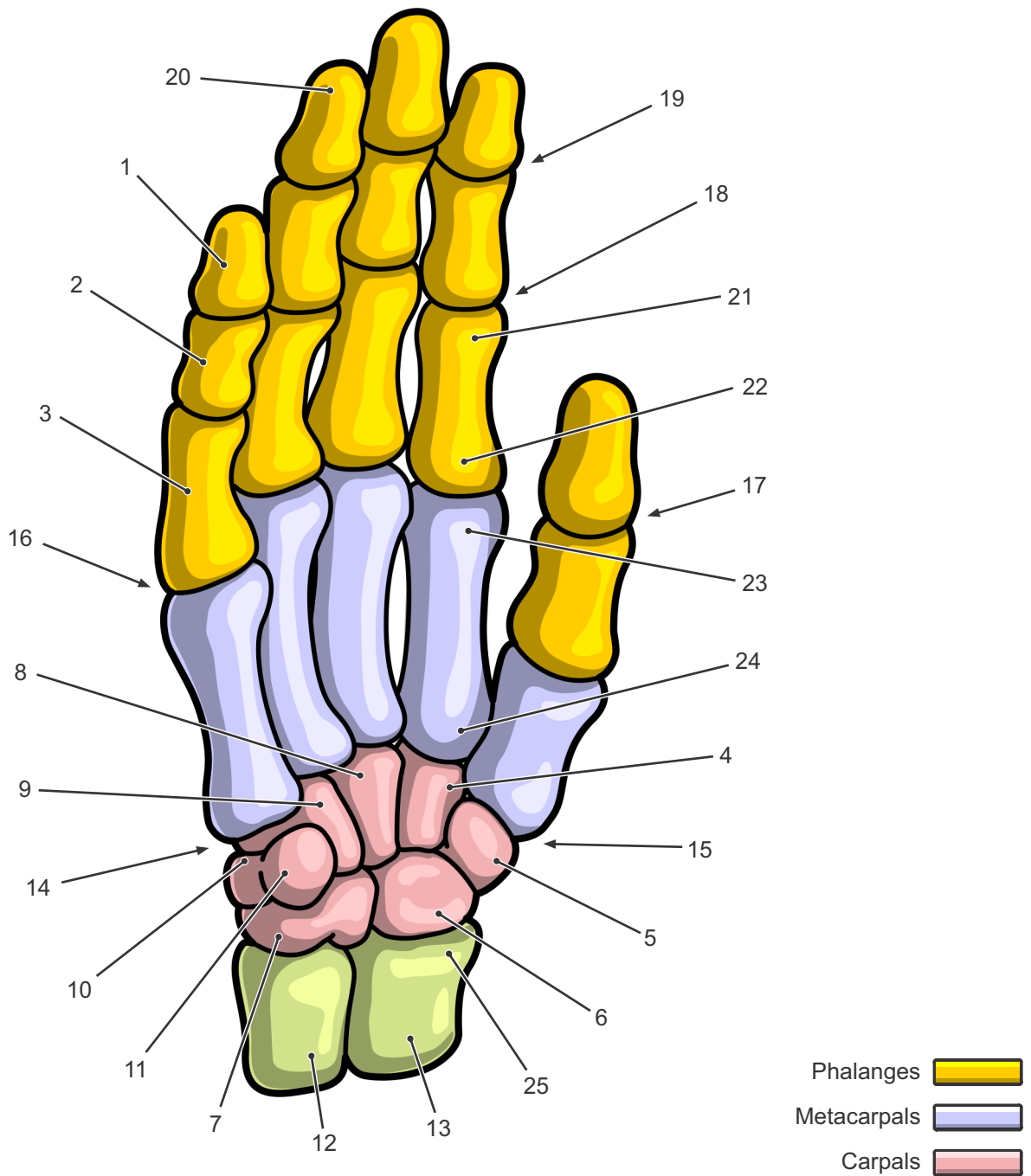


Bones of the Human Hand



- 1·Distal Phalanges
- 2·Middle Phalanges
- 3·Proximal Phalanges
- 4·Trapezoid
- 5·Trapezium
- 6·Scaphoid
- 7·Lunate
- 8·Capitate
- 9·Hamate

- 10·Triquetrum
- 11·Pisiform
- 12·Ulna
- 13·Radius
- 14·Carpometacarpal (CMC) Joint
- 15·Trapeziometacarpal Joint (also first CMC)
- 16·Metacarpophalangeal (MCP) Joint
- 17·Interphalangeal Joint
- 18·Proximal Interphalangeal Joints (PIJ/PIP)

- 19·Distal Interphalangeal Joints (DIJ/DIP)
- 20·Tuberosity of Distal Phalanx
- 21·Ossis phalangis
- 22·Basis phalangis
- 23·Caput Ossis Metacarpi
- 24·Basis Ossis Metacarpi
- 25·Processus styloideus radii